

## CASE RECORD

### A big urinary calculus expelled with homoeopathic medicine

A.K. Gupta<sup>1\*</sup>, Jaya Gupta<sup>2</sup>, V.A. Siddiqui<sup>2</sup> & Alok Mishra<sup>2</sup>

<sup>1</sup> Homoeopathic Drug Research Institute, Lucknow, India

<sup>2</sup> Central Council for Research in Homoeopathy, New Delhi, India

**Urinary stones of up to 5 mm. of diameter are known to pass spontaneously through the urinary tract, whereas those exceeding 7 mm. of diameter almost always require surgical intervention. A case of 16.9 mm calculus, lodged close to left uretero-vesicular junction, presented with severe cramping pain in the left lumbar region, which radiated downwards to the groin area. Patient also had severe pain at the end of urination. After analysing the totality of symptoms presented by the patient, Sarsaparilla 30C was prescribed. Three doses of this homoeopathic medicine could expel the stone, without causing considerable discomfort or bleeding.**

**Key Words:** urinary calculi; homoeopathy; sarsaparilla; uretero-vesicular junction

### Introduction

Urinary stones are the third most common affliction of the urinary tract. They are exceeded only by urinary tract infections and pathological conditions of the prostate<sup>1</sup>. Urolithiasis affects 5-15% of the population worldwide. Recurrence rates are close to 50% and the cost of treatment for urolithiasis to individuals and society is high.<sup>2</sup> Data indicates that up to 98% of urinary tract stones with size less than 5 mm in diameter, especially in the distal ureter, pass spontaneously<sup>3</sup>. Stones of size 5–7 mm have a modest chance (50%) of passage, and those greater than 7 mm almost always require surgical intervention<sup>4</sup>. Stones at the uretero-vesicular junction often cause dysuria and frequent urination, which is mistaken for infection.<sup>5</sup> Shock wave lithotripsy is recommended as the first line of conventional treatment for most of the patients with stones more than 5 mm in the proximal ureter, whereas both shock wave lithotripsy and ureteroscopy are acceptable ways of treatment for stones in the distal ureter<sup>2</sup>. However, there is sufficient evidence in literature that shock wave lithotripsy is associated with increased chance of renal injury<sup>6</sup>.

Homoeopathic literature provides a good scope for treating cases of urolithiasis<sup>7,8</sup>, but due to poor

documentation of case reports and studies, the role of homoeopathic therapy and its cost effectiveness remain a subject of discussion in the minds of research personnel. The present case brings to light the efficacy of a single homoeopathic medicine in the treatment of a nearly surgical case, leading to expulsion of the stone without causing much discomfort. The case will provoke the readers, including the researchers, to further explore the utility of Homoeopathy for treatment of such cases.

### Case Presentation

An obese, dark-complexioned male of 50 years presented with a history of cramping pain in the left lumbar region. The pain, present since three months, radiated downwards to the groin. Dysuria with increased frequency and urgency of urination were other complaints. The patient also developed burning sensation while urinating and increased pain at the end of micturition over a period of three months. The patient could pass urine only drop-by-drop while sitting, but freely while standing. The patient also had metallic taste in mouth and no thirst. A tendency to catch cold easily and taking offence from the remarks of people were other characteristics of the patient. Except for a few analgesics during acute episodes of colicky pain, the patient had taken no medical treatment for his problem.

A thorough physical examination of the patient revealed no abnormal findings. Routine haemogram

\* Address for correspondence:

Homoeopathic Drug Research Institute  
National Homoeopathic Medical College & Hospital campus  
1, Viraj Khand, Gomti Nagar  
LUCKNOW - 226010 (U.P.), India  
Email Id: hdri\_lko@yahoo.com

and serum calcium levels and the elements of renal function tests like blood urea, blood urea nitrogen and serum albumin levels were found to be within normal range. Only serum creatinine was elevated to 1.24 mg% (Normal Range: 0.7 – 1.1 mg% for males). Ultrasonography-KUB (Fig. 2a) revealed a 16.9 mm calculus at uretero-vesicular junction, not moving with the change of posture. There was no sign of hydronephrosis or any obstruction to the outflow of urine. Apart from the calculus, USG report also revealed a heavier prostate gland, with 31.5 gms. of weight (Average weight: 20 gms.) and a significant post-voidal residual urine of 10 cc in the bladder.

Assessment of severity of disease condition was done at the entry level and then during all the 14 follow up visits. The Baseline Assessment Scoring Form (Table 1), containing 8 items (pain, haematuria, dysuria,

number of stones, size of stone, position of stone in kidney/ ureter/ bladder) was filled up during each visit. These symptoms were rated on 4-point scale, based on the severity of symptoms, from '0' meaning 'absent' to '3' meaning 'severe'. A total of these symptoms score was again rated under three categories of mild (score 1-7), moderate (score 8-14) and severe (score 15-23).

At the time of entry, the symptom score of the patient was *moderate*, totaling to 12. Based on the totality of symptoms, the rubrics were selected for repertorisation using CARA Professional homeopathic software, version 1.4. *Sarsaparilla* turned out to be the leading medicine in the repertorisation analysis, covering maximum rubrics (12) and scoring highest points (20) (Fig. 3). *Sarsaparilla* 30C (10<sup>-60</sup> dilution) one dose, was prescribed, followed by placebo for the rest of the day. Patient was also advised for dietary

**Table 1: Baseline assessment score**

Assessment on First visit (Circle relevant number on each line)				
1. Pain/colic	0 No pain	1 Mild pain	2 Moderate pain	③ Severe pain
2. Haematuria	0 No Haematuria	① Microscopic	2 Persistent	3 Gross
3. Dysuria	0 No Dysuria	1 Mild Dysuria	2 Moderate Dysuria	③ Severe
4. Stone		① Single stone	2 Multiple stone	
5. Size of stones	0 Gravel < 03 mm	1 3 mm -< 4 mm	2 4 mm -<5 mm	③ 5 mm and above
6. Position of stone kidney	① no stone in kidney	1 Pelvic ureteric junction	2 Pelvis of Kidney	3 Calyces of kidney
7. Position of stone ureter	0 no stone in ureter	① Lower part of ureter	2 Middle of ureter	3 Upper part of ureter
8. Position of stone bladder	① no stone in bladder	1 Base of bladder	2 Intramural ureter	
Total scoring – 12				
Symptoms score – (Sum of 8 circled numbers)				
1-7 mild		8-14 moderate		15-22 severe
Severity of the case: Moderate				

management like increased intake of plenty of water, avoidance of spinach etc. Within 24 hours of intake of *Sarsaparilla* 30C, the patient developed severe pain while voiding urine, following which *Sarsaparilla* 30C was prescribed for three times a day for two days,. However, after consuming only two doses of medicine, the patient developed more severe pain and with this severe pain, the stone was expelled while voiding urine.

After expulsion of the stone, Ultrasonography-KUB (Fig. 2b) was again performed, which revealed no calculus. However, a significant volume of post-voidal residual urine was reported in the bladder, which was gradually resolved without medication. No medicine was given in the follow ups after the expulsion of stone, as the symptom score in the assessment form was '0' (Table 2). A repeat USG report at the end of treatment

**Table 2: Follow up**

Date	Main symptom	Laboratory findings	Symptom score	Medicine prescribed
12.11.07	Severe pain in the left lumbar region, radiating downwards to groin area.	USG (KUB): Renal calculus of 16.9 mm at left UVJ, post-voidal residual urine: 10 cc and prostate weight of 31.5 gm Renal Function Test: Serum creatinine (1.24 mg %)	12	<i>Sarsaparilla</i> 30/ 1 dose
13.11.07	Severe pain at close of urination	–	12	<i>Sarsaparilla</i> 30/ TDS for 2 days
14.11.07	Stone expelled; microscopic haematuria	USG (KUB): Normal scan	0	<i>Sac.lac.</i>
21.11.07	Normal	–	0	<i>Sac.lac.</i>
16.1.08	Normal	–	0	<i>Sac.lac.</i>
3.4.08	Normal	–	0	<i>Sac.lac.</i>
15.4.08	Normal	USG (KUB): Normal scan; no impression of any renal calculi; residual post-voidal urine 10 cc.; prostate weight: 20 gm	0	<i>Sac.lac.</i>
30.4.08	Normal	–	0	<i>Sac.lac.</i>
28.5.08	Normal	–	0	<i>Sac.lac.</i>
30.7.08	Normal	–	0	<i>Sac.lac.</i>
8.9.08	Backache	USG (KUB): Normal scan; no impression of any renal calculi; residual post-voidal urine insignificant.; prostate weight: 20 gm Renal Function Test: Serum creatinine: 0.8 mg%	0	<i>Calc. fluor.</i> 30/ 2 doses
16.9.08	Gas formation, indigestion; no backache	–	1	<i>Nux vomica</i> 30/ 2 doses
17.11.08	Normal	–	0	<i>Sac.lac.</i>

showed a reduced weight of prostate gland (20 gms.) and an insignificant amount of post-voidal residual urine (Table 2). Also, the renal function test revealed a normal value of serum creatinine (0.8 mg%). After expulsion, the size of stone was measured, the maximum length of which was 13 mm., whereas maximum width was 9 mm. (Fig. 1). The size of stone, as revealed in the first USG report, was 16.9 mm. The reason for reduction in the dimensions of the stone during expulsion is expected to be the effect of medicine on the stone. The first and then the subsequent doses of the medicine might have dissolved the stone to some extent, which would have gone unnoticed by the patient while passing urine.

Patient was followed up for one year without any complication or treatment sequel. Patient required no other medicinal intervention, except a few doses of *Calcarea fluoricum* and *Nux vomica* for backache and gastric derangements respectively.

### Discussion

The modern school of Medicine maintains that a urinary calculus of more than 7 mm diameter usually requires surgical intervention<sup>4</sup>, but the case presented here calls for further probing on this outlook. The case clearly reflects the potential of Homoeopathy in treating urinary calculi, even of the size as large as 16.9 mm. The homoeopathic treatment not only spared the patient of the impending surgery, but it also showed excellent results within a short time period. Only three doses could lead to the expulsion of stone without any considerable damage to the urinary tract. This not only brings to surface an indisputable efficacy of Homoeopathy in treating such cases, but also testifies the information about the treatment of such cases, as available in the homoeopathic literature of olden years.

Moreover, considering the fact that the management of stone disease can be more difficult in obese patients<sup>9</sup>, the conventional treatment through extracorporeal shockwave lithotripsy and surgery could have been challenging in this case. So, the outcome of the present case treatment suggests that Homoeopathy can be a better treatment modality for such a large urinary stone, especially in obese patients where the extra amount of fat becomes an obstacle in many ways.

Contrary to the common understanding of homoeopaths for Sarsaparilla as a right-sided medicine, the medicine could expel a left-sided stone equally effectively. This emphasises the need for further research and verification of the homoeopathic medicines in general, and of Sarsaparilla, in particular, to add to the present *Materia Medica*. The selection of Sarsaparilla on the basis of totality of symptoms helped the investigator rule out the right-side affinity of the medicine as a barrier to its prescription. The unbiased prescription of this medicine led to the desirable results in the homoeopathic way. An aggravation of symptoms like intensified pain and discomfort, followed by expulsion of the stone while voiding urine is the natural course of recovery for this condition. A right similimum could help the body follow the recovery route and provide relief to the patient. It is felt by the authors that a similar use of this medicine should be tried by the profession for further confirmation and verification of this observation. Clinical trials, oriented on this observation, could contribute to the existing knowledge of this medicine and thereby enrich the *Materia Medica* for its future use.

The case, however, leaves to the researchers a few questions open to discussion. These include the stimulating points like, 'how could a stone of size 16.9 mm be located at the uretero-vesicular junction, without



Width of the stone: 9 mm.



Length of the stone: 13 mm.

Figure 1: Dimensions of stone expelled after administration of Sarsaparilla 30C



A big urinary calculus expelled with homoeopathic medicine  
A.K. Gupta *et al*

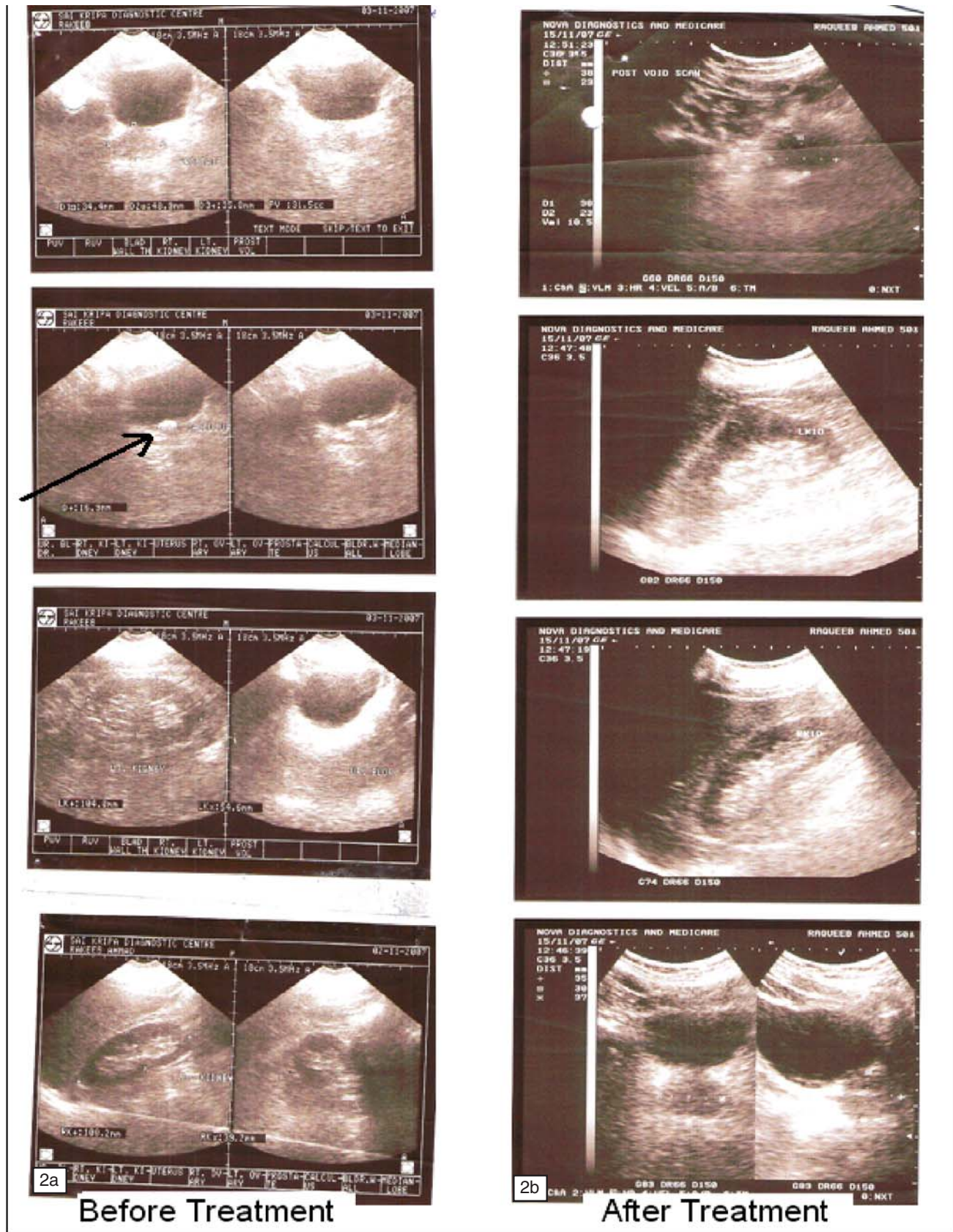


Figure 2: USG reports, before (3.11.07) and after (9.9.08) treatment

Weighted	Sars	Calc	Lyc	Caust	Merc	Puls	Nit-ac	Nux-v	Ars	Sep	Sulph	Alum	Kali-c	Nat-c	Nat-m	Ph-ac	Phos	Rhus-t	Canth	Sil	Arg-n	Bell	Berb	Colch	Med	Thuja	Apis	Bly	Cann-s	Acon		
Weighted	20	18	18	17	17	17	18	16	15	14	14	13	13	13	13	13	13	13	12	12	11	11	11	11	11	11	10	10	10	10		
Rubrics weighted	12	9	9	9	8	8	8	7	7	7	9	8	7	7	8	6	8	7	6	7	6	7	6	5	8	7	5	5	6	6		
Rubric grades	20	18	18	17	17	17	16	16	15	14	14	13	13	13	13	13	13	13	12	12	11	11	11	11	11	10	10	10	10			
PAIN General left	Complete. Kidneys																															
PAIN General region of extending to down	Complete. Kidneys	2																														
PAIN cramping	Complete. Kidneys	1	1	2	3		2				1				1																	
URINATION frequent daytime night, and	Complete. Bladder	1	2		2	3							2	1		2		1	2	2												
URINATION dribbling by drops sitting, while	Complete. Bladder	2																														
PAIN General urination close of. at	Complete. Urethra	3.		1	1	2	2	1			1				3		1				1					1	1				2	
PAIN burning	Complete. Urethra	2	2	2	2	3	2	2	3	2	3	1	1	2	1	2	2	1	3	3	2	1	3	2	1	3	2	2	3	1		
METALLIC	Complete. Taste	1,	2	2	3	1		2	2	2	2	1	1	3			1	3	2	1	2	1										
COLD tendency to take. taking cold agg.	Complete. General	1,	3	3	1	3	2	3	2	3	2	3	2	3	2	2	2	2	2	2	3	2	2		1	3	2				3	3
COMPLEXION dark. brunette	Complete. General	1	2	1	3	1	3	3	2	1	1	1	1	3	1	1	3	3	3		1		1				1		2	1	2	
THIRSTLESSNESS	Complete. Stomach	1	1	2	1	1	3	2	1	2	2	1	1	2	1	1	3	1	1	1	1	2	2	1	3	1	1	3	1	1	1	
OFFENDED easily	Complete. Mentals	2	3	3	3	1	2	1	3	3	2	2	2		1	2		1			2		2			1	1	2		1	2	
PAIN General	Complete. Kidneys	3	2	2	1		2	2	2	2	2	1	2	2	2	2	2	1	3	1	2	2	3	3	2	2	2	2	2	2	1	

Figure 3: Repertorisation Chart

causing hydronephrosis or obstruction to the outflow of urine’; ‘what mechanism was involved after administration of *Sarsaparilla 30C*, which allowed 16.9 mm stone to pass through urethra without causing any gross injury or haematuria, especially while passing through the membranous part of urethra’, and ‘could *Sarsaparilla* cause dilatation of urethra to allow the passage of 16.9 mm stone without causing any injury’?

**Acknowledgements**

1. Prof. C. Nayak, Director, CCRH, for correcting the manuscript of the article.
2. Dr. Harleen Kaur, Communication Consultant, CCRH, for assisting in writing the article.

**References**

1. D.S. Qaader, S.Y. Yousif and L.K. Mahdi. Prevalence and etiology of urinary stones in hospitalized patients in Baghdad. *Eastern Mediterranean Health Journal* 2006; 12 (6): 853-61.
2. Zarse CA, et al. Helical computed tomography accurately reports urinary stone composition using attenuation values: in vitro verification using high-resolution micro-

3. Segura JW, Preminger GM, Assimos DG, Dretler SP, Kahn RI, Lingeman JE, Macaluso JN Jr. Ureteral Stones Clinical Guidelines Panel summary report on the management of ureteral calculi. *The American Urological Association. J Urol.* 1997 Nov; 158(5): 1915-21.
4. Zarse CA, et al. Helical computed tomography accurately reports urinary stone composition using attenuation values: in vitro verification using high-resolution micro-computed tomography calibrated to fourier transform infrared microspectroscopy. *Urology.* 2004; 63:828–833.
5. D.S. Qaader, S.Y. Yousif and L.K. Mahdi. Prevalence and etiology of urinary stones in hospitalized patients in Baghdad. *Eastern Mediterranean Health Journal* 2006; 12 (6): 853-61.
6. McAteer JA, Evan AP, Williams JC Jr, Lingeman JE. Treatment protocols to reduce renal injury during shock wave lithotripsy. *Curr Opin Urol.* 2009 Mar; 19(2): 192-5.
7. Williams HN. *Thlaspi bursa pastoris* in the treatment of kidney stones. *J Am Inst Homeopath* 1988 Mar; 81(1): 31-32.
8. Hunton M. Two cases from general practice. *Simile* 1996 Jan; 6(1):10.
9. Vujovic A, Keoghane S. Management of renal stone disease in obese patients. *Nat Clin Pract Urol.* 2007 Dec;4(12):671-6.