

CASE RECORD

A case of vitiligo treated with phosphorus

Ravi Kumar S.

Clinical Research Unit (Homoeopathy), Chennai

Abstract

Vitiligo a disease of cosmetic problem has much psychosocial impact. The success rate in treating this condition in conventional medicines is limited and sometimes, treatment follows with side effects. Though a few case records are documented in the past about the success of various homoeopathic medicines, yet they lack proper quantitative assessment. This is a case documented from the ongoing clinical research study on vitiligo at Clinical Research Unit (Homoeopathy), Chennai. The case was treated with Phosphorus over a period of 17 months with steady improvement which is evident from the photographs and improvement in baseline scores of presentation of the case. The outcome of the ongoing multicentric clinical research study will reveal further regarding the effect of homoeopathic medicine in Vitiligo.

Keywords: homoeopathy; vitiligo; segmentary vitiligo; phosphorus

Introduction

Vitiligo is an acquired loss of pigmentation characterized histologically by absence of epidermal melanocytes. The word vitiligo is derived from the Greek word 'vitilius', meaning 'calf'. The white spots of vitiligo resemble white patches on a calf. It may be an autoimmune disease associated with antibodies (vitiligo antibodies) to melanocytes. Studies suggest there is some genetic mechanism involved in the etiology of vitiligo and that it is polygenic in nature¹.

Vitiligo has much psychosocial impact. Many studies show that there is a lot of social stigma, low self esteem, adjustment disorder, poor body image and low quality of life associated with vitiligo patients²⁻¹⁰. Though it is usually known that vitiligo is only a cosmetic problem, yet a number of conditions may occur in association with vitiligo¹¹.

Various systems of medicine have claimed to have good results but not without side effects, like erythema, xerodermia, pruritus, acne form pustules and telangiectasia¹².

Few case records have been documented in the past showing the effectiveness of homoeopathy in the

treatment of vitiligo¹³⁻²⁰. But no where a quantitative assessment of the patches on the basis of some score or scale has been attempted. This is one of the case records of segmental vitiligo, which documents the effect of homoeopathic medicine through quantitative evaluation.

Data collection

The case was selected from the OPD of Clinical Research Unit, Chennai, where a research project on vitiligo is going on. Case was enrolled as per the protocol of the clinical study on vitiligo and accordingly baseline assessment was done (table-2). The assesment score chart (table-1) was developed by Central Council for Research in Homoeopathy for its ongoing project on clinical research study on vitiligo. The photographs were also taken at a fixed intervals.

Case summary

The patient, a girl of 10 years old, presented with de-pigmented patches behind both ears (pic.2 and 3), below the right knee (antero-medial aspect of rt. lower limb 2 inches below rt. knee)(pic. 4), back of neck extended up to occiput with white hairs of the patch [nape of neck and occiput] (pic.1), for last 2 years. Lesions started first behind both ears as small patches, and later, on other parts of body. Spread of the patches was very slow. Patient had received conventional treatment for a period of one year without any improvement.

Address for Correspondence:
Ravi Kumar S., Research Officer,
Clinical Research Unit (Homoeopathy),
M-103/4, Kalakshetra colony, 30th Street,
Besant nagar, Chennai-600090. India
Tel.044-24911821
E-mail-drrvkumar64@gmail.com

A case of vitiligo treated with phosphorus
Ravi Kumar S.

Patient had desire for open air, fruits, fried food, fish, ice cream and meat. She could not tolerate warmth. Mentally the patient was childish, quarrelsome, tearful with alternate cheerfulness; had fear of being alone, cockroaches; intolerant to contradiction and threw herself on floor when angry.

There is no family history of vitiligo. Her childhood history had no significant events. On examination it was found that she had no systemic problem; fair complexion; thin body built; weight 31kgs, height 152cms.

Table-1: Assessment score chart

Type	0 Improving	1 Stationary	2 Resistant	3 Progressive
Site of the lesion		1 Follicular	2 Mucosal	3 Acral
No of Patches	0 Absent	1 Single patch	2 Segmentary	3 Generalized/Universal
Hair in patch	0 Black		2 White	
Margins of patch		1 Normal	2 Inflamed	
Colour of patch	0 Normal (Body colour)	1 Pigment spots on patch	2 Pink/red	3 Milky white
Re-pigmentation	0 Fully pigmented	1 Perifollicular pigmentation	2 Hyper-pigmentation of margins	3 No pigmentation
Grading Score	MILD (2 - 6)	MODERATE (7 -12)		SEVERE (13- 19)

Table-2: Baseline assessment score of the patient on first visit

Type		3 Progressive
Site of the lesion	1 Follicular	
No of Patches		2 Segmentary
Hair in patch		2 White
Margins of patch	1 Normal	
Colour of patch		3 Milky white
Re-pigmentation		3 No pigmentation
Grade - Severe Total score-15		

Follow up of the patient was done periodically at fixed intervals as per protocol.

Complete repertory [Hopath Classic 8.0 Version] was referred for repertorisation of the case. The following symptoms were considered for repertorization. The repertorization chart (table 3) is given below.

The first prescription was *Phosphorus*, which, on reportorial analysis, scored highest marks (15), covering 9 rubrics out of 12. The follow ups along with scoring of the case are given in the table - 4.

Discussion and Conclusion

Phosphorus was selected after considering the mental generals, physical generals and particular symptoms of the patient. On reportorial analysis, Phosphorus has scored highest marks (15) covering

most of the rubrics (9 out of 12). Hence *Phosphorus* in 30C potency, single dose was prescribed followed by placebo. The second dose of *Phosphorus* in 30C potency, single dose was administered after a gap of 3 months, when the improvement became standstill. Thereafter, the patient has been on placebo, till date, with continuous steady improvement and still under treatment. The improvement of the patient reaffirms the principles of single medicine, minimum dose and infrequent repetition as advocated by Hahnemann²¹.

This is a case, which speaks about the success of Homoeopathy in the management of vitiligo. The outcome of the ongoing multicentric clinical research study at various centres of Central Council for Research in Homoeopathy will reveal further regarding the effect of homoeopathic medicine in the patients suffering from vitiligo.

Table-3: Repertorization chart

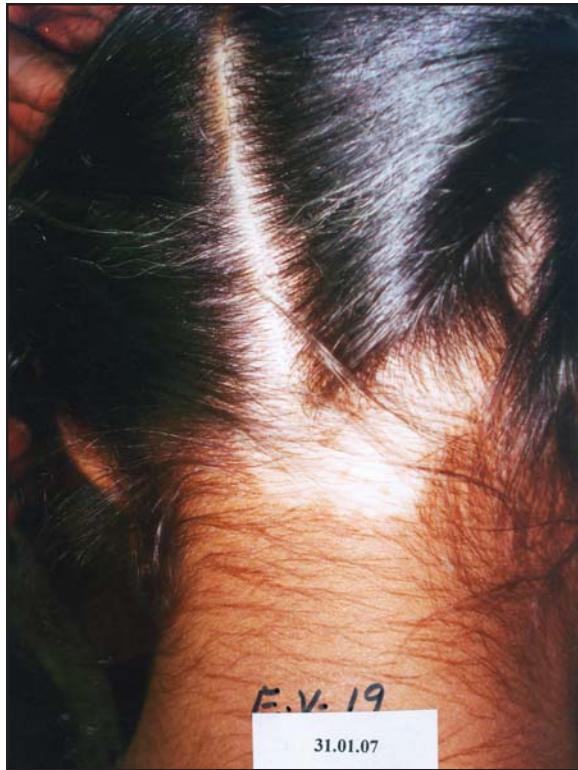Normal Repertorisation		Totally Symptoms Covered	Phos	Med	Nat-m	Sulph	Alum	Ars	Calc	Nit-ac	Sil	Stram	Thuja	Kali-i	Nat-c	Verat	Ant-t
			15	13	12	12	11	11	10	10	10	10	9	8	8	8	8
[C] [Mind]Quarrelsome, scolding:		9	9	8	6	7	6	7	6	6	6	4	6	5	5	4	5
[C] [Mind]Contradiction:Intolerant of:Throw themselves angrily on the fl.		2	1	2	3	1	2	1	2	2	2	2	2	1	2	2	1
[C] [Mind]Weeping, tearful mood:Tendency:Alternating with:Cheerfulne						1						2					
[C] [Mind]Fear:Alone, of being:Night:			2									4					
[C] [Mind]Fear:Animals, of:Cockroaches, of:		2				1											
[C] [Generalities]Food and drinks:Meat (see meat, aversion, fat):Desire		1	2	1	2		1	1	3	1					1		
[C] [Generalities]Food and drinks:Fish:Desires:		1	2	2					2					2			
[C] [Generalities]Food and drinks:Ice-cream:Desires:		3	2	1	1			2		2						1	
[C] [Generalities]Food and drinks:Fruit:Desires:		1	1	1		2	1	1					1			3	2
[C] [Generalities]Warmth:Agg.:		2	1	3	3	3	1	2	1	1	1	1	2	3	1	2	2
[C] [Skin]Discoloration:White:		1	1	1	1	1	3	1	1	1			1	1	2		1
[C] [Skin]Discoloration:White:Spots, vitiligo:		2	1	1	2	2	3	2	1	3			1	1	2		1

Table-4: Follow ups along with score

		Follow ups					
		At entry					
Date		31.1.07	14.2.07	09.05.07	12.7.07	18.6.08	
Vitiligo areas	<ul style="list-style-type: none"> • Back sides of both ears • Below the right knee [anteromedial aspect of rt. lower limb, 2 inches below right knee] • Back side of neck [occiput and nape of neck] with white hair. 	<ul style="list-style-type: none"> • Back sides of both ears • Below the right knee [anteromedial aspect of rt. lower limb, 2 inches below right knee] • Back side of neck [occiput and nape of neck] with white hair. <p>There was no change in number of patches, no change in color of patch, mild perifollicular pigmentation observed in the margin of the patches.</p>	<ul style="list-style-type: none"> • Back sides of both ears • Below the right knee [anteromedial aspect of rt. lower limb, 2 inches below right knee] • Back side of neck [occiput and nape of neck] with white hair. <p>Note: <i>Improvement became static.</i></p>	<ul style="list-style-type: none"> • Back sides of both ears • Below the right knee [anteromedial aspect of rt. lower limb, 2 inches below Right. knee] • Back side of neck [occiput and nape of neck] with grey hair. <p>The patches are improving to normal skin and the hair becoming grey in color</p>	<ul style="list-style-type: none"> • Back sides of both ears completely covered with repigmentation and showed normal skin • Below the right knee [anteromedial aspect of rt. Lower limb, 2 inches below right. knee] almost covered with repigmentation • Back side of neck [occiput and nape of neck] with grey hair-completely covered with repigmentation and showed normal skin. 		
Score	Picture (1, 4, 7, 10)	15	11	09	07	0	
Medicine	Phosphorus 30C, single dose with placebo	Phosphorus 30C, single dose with placebo	Placebo	Phosphorus 30C, single dose with placebo	Placebo	Placebo	
	Picture (3, 6, 9, 12)						

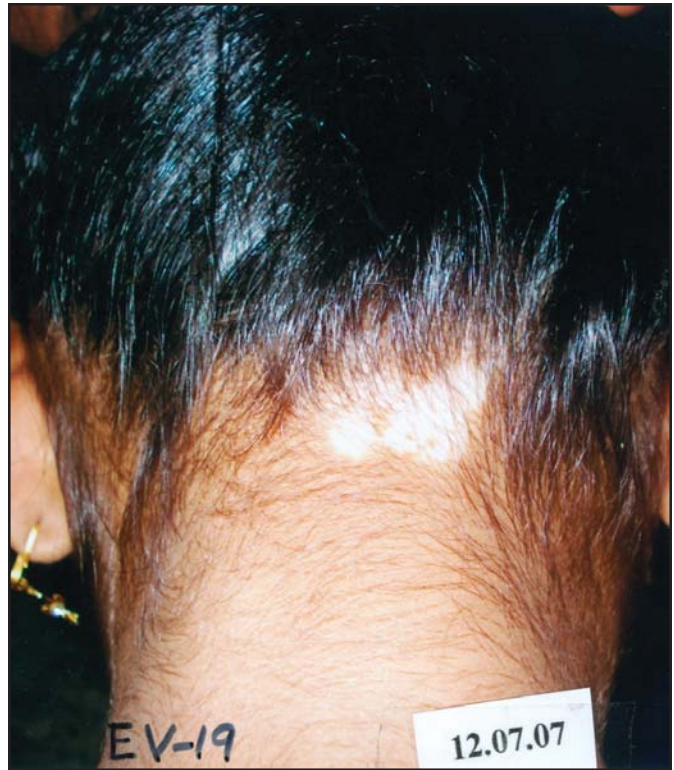Photographs showing the Vitiligo patches at different locations at entry and during treatment

At entry on 31.1.2007



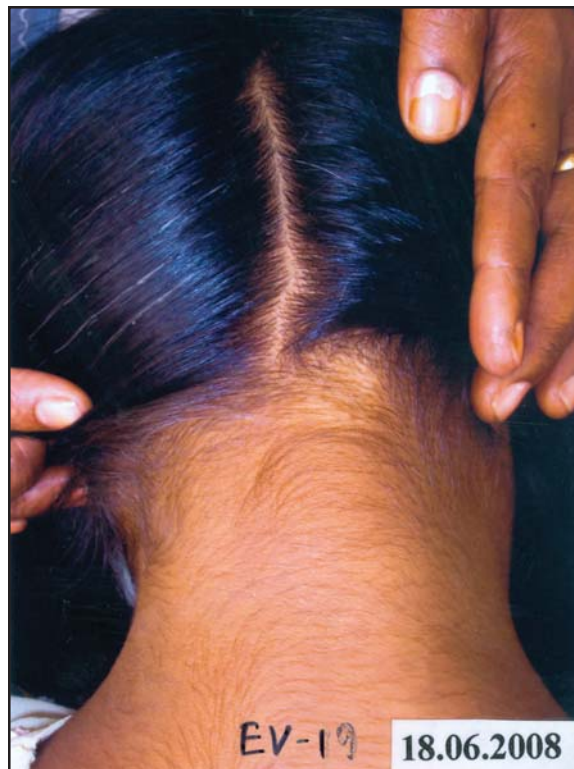Pic. 1

During treatment as on 12.7.2007



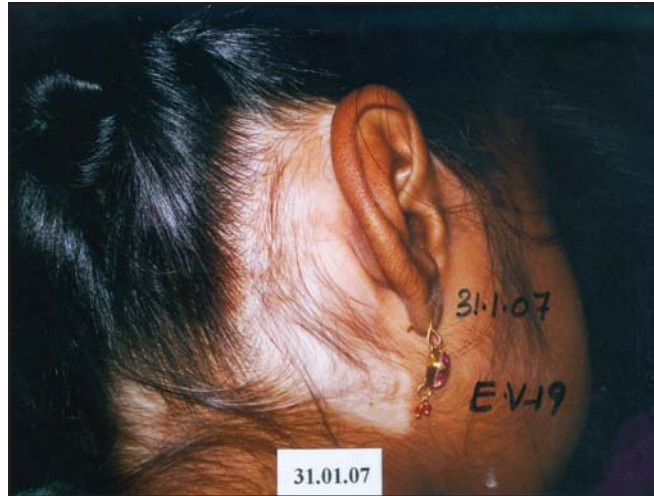Pic. 2

During treatment as on 18.6.2008



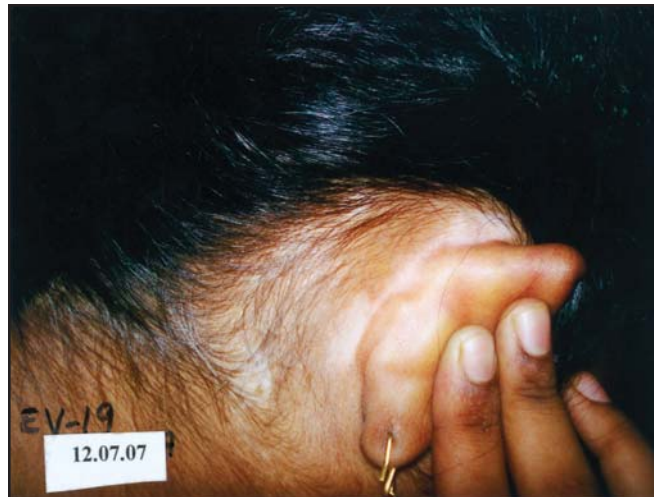Pic. 3

At entry on 31.1.2007



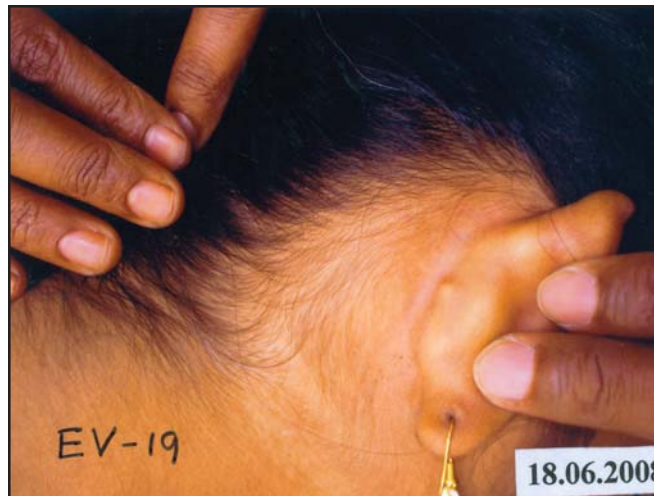
Pic. 4

During treatment as on 12.7.2007



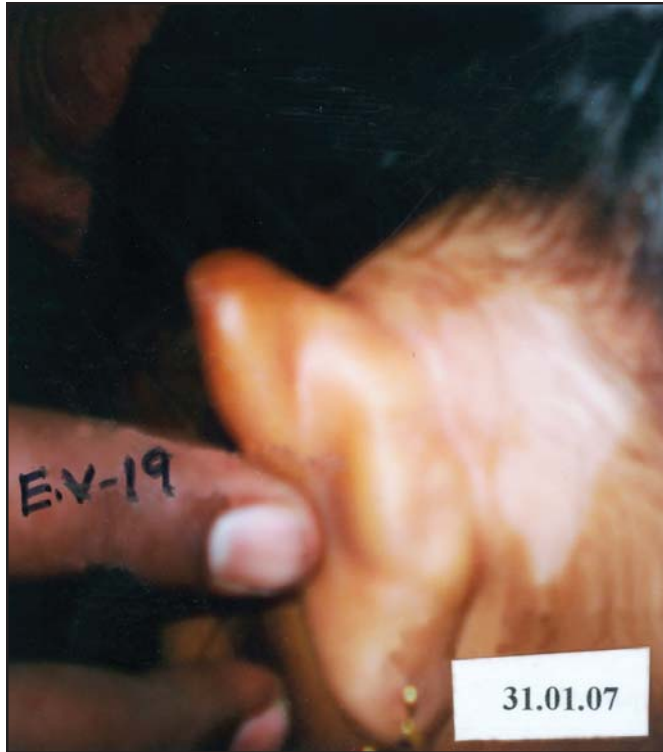
Pic. 5

During treatment as on 18.6.2008



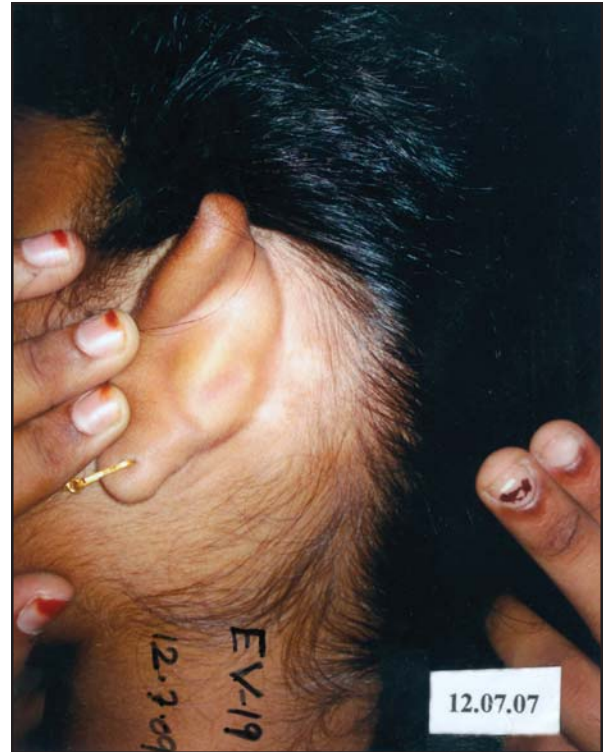Pic. 6

At entry on 31.1.2007



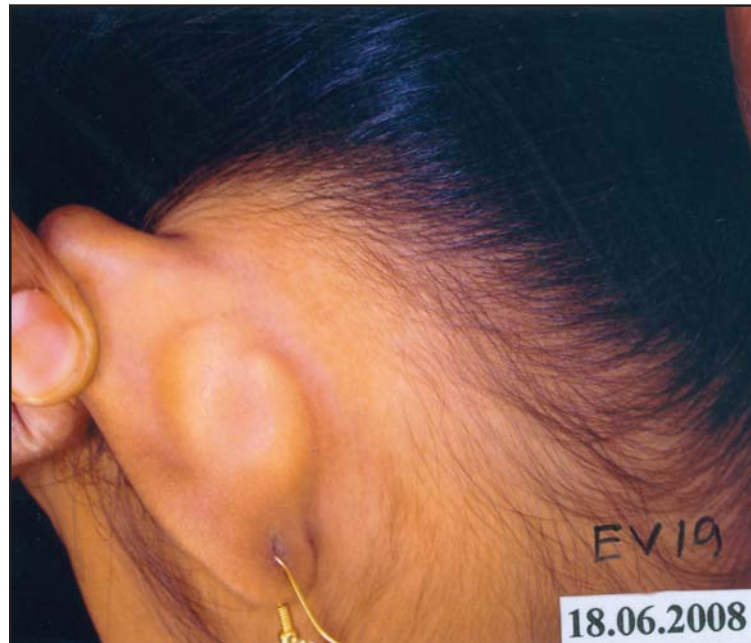Pic. 7

During treatment as on 12.7.2007



Pic. 8

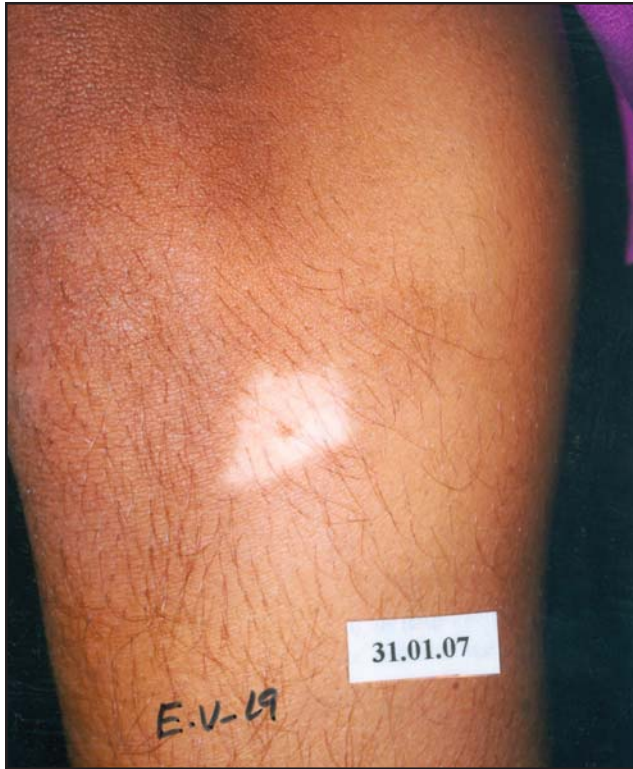During treatment as on 18.6.2008



Pic. 9

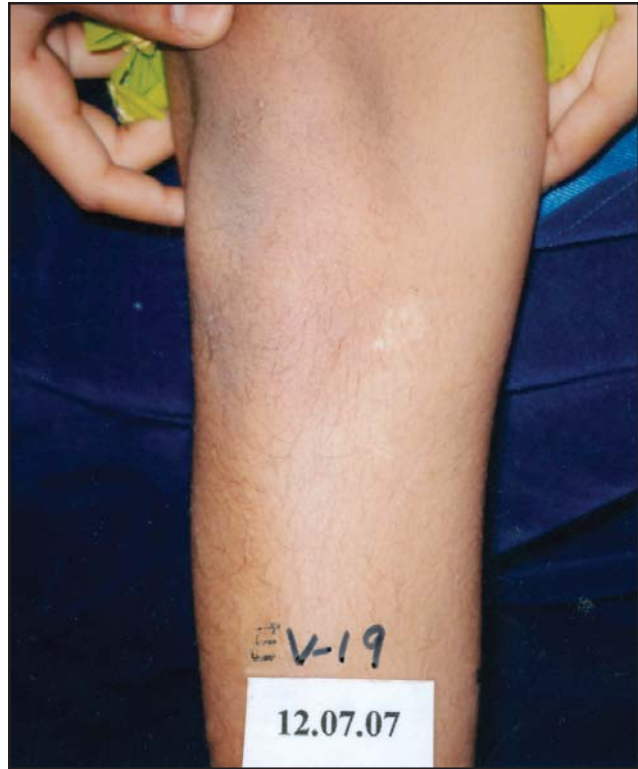A case of vitiligo treated with phosphorus
Ravi Kumar S.

At entry on 31.1.2007



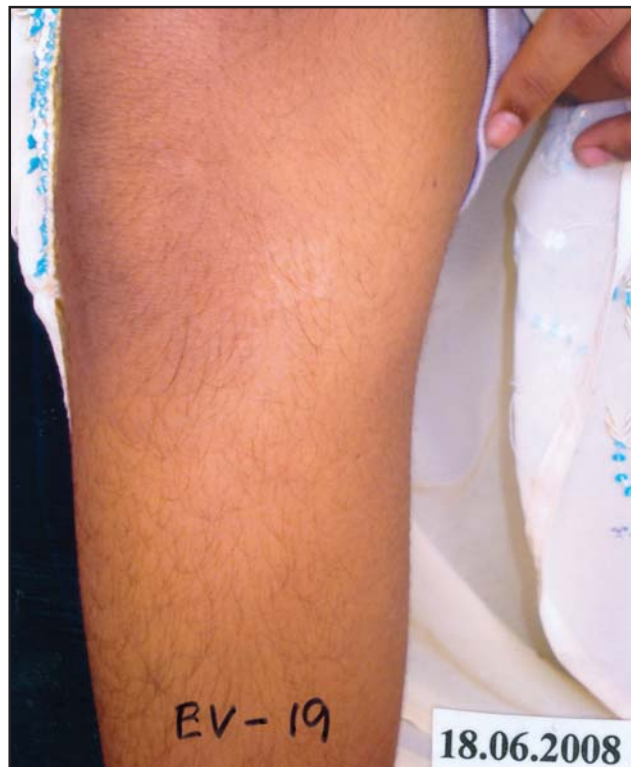Pic. 10

During treatment as on 12.7.2007



Pic. 11

During treatment as on 18.6.2008



Pic. 12

Acknowledgements

Author is indebted to the consultant Dr. Priya Naresh, MBBS, D.N.B (Skin) for her timely guidance in periodical monitoring of the case. A special thanks to Dr. P.S. Chakraborty, R.O. (H), Dr. Debadatta Nayak, Dr. V. Roja, Senior Research Fellows of CCRH headquarters for preparing the write up for the journal. Last but not the least, the patient and her guardian are acknowledged for their consent to publish this report and photographs.

References

1. Habif P. Thomas, Clinical Dermatology: A Color Guide to Diagnosis and Therapy;(CD-ROM) Mosby-Year Book, In, 1996.
2. Porter JR, et al .*Psychosocial effect of vitiligo: a comparison of vitiligo patients with "normal" control subjects, with psoriasis patients, and with patients with other pigmentary disorders*; Journal of American Academy of Dermatology. 1986. Aug; 15(2 Pt 1):220-4.
3. Mattoo SK et al, *Psychiatric morbidity in vitiligo: prevalence and correlates in India*; Journal of European Academy of Dermatology and Venerology. 2002; Nov;16(6):573-8.
4. Davinder Parsad, Dogra Sunil and Kanwar Amrinder Jit. *Quality of life in patients with vitiligo*; Health and Quality of Life Outcomes. 2003, 1 accessed BioMed Central Ltd.
5. Parsad D. *Department of Dermatology, Postgraduate Institute of Medical Education and Research, Chandigarh 160012, India E-mail: dprs@satyam.net.in et al . Dermatology Life Quality Index score in vitiligo and its impact on the treatment outcome*;British Journal of Dermatology. 2003;148 (2):373–374.
6. Firooz Alireza et al. *What patients with vitiligo believe about their condition*; International Journal of Dermatology. 2004; 43(11): 811-814.
7. Ongenae K et al. *Effect of vitiligo on self-reported health-related quality of life*; British Journal of Dermatology. 2005; 152(6): 1165-1172.
8. Ongenae K et al. *Psychological effects of Vitiligo*; Journal of European Academy of Dermatology and Venerology. 2006; 20(1):1-8,.
9. Ott G Schmid et al. *Stigmatization experience, coping and sense of coherence in vitiligo patients*; Journal of European Academy of Dermatology and Venerology. 2007; 21 (4), 456-461.
10. Manoolache Liana, Benea Vasile; *Stress in patients with alopecia and vitiligo*, Journal of European Academy of Dermatology and Venerology. 2007; 21 (7):921-928.
11. Bleehens S.S. Disorders of Skin Colour; Text book of Dermatology, vol.2, 6th edition, Blackwell Science Publishers, 1998; pp802-805.
12. Forschner Tobias, Buchholtz Stefan, Stockfleth Eggert. *Current state of vitiligo therapy – evidence-based analysis of the literature*; JDDG ;6: 2007 (Band 5): 467:475.
13. Koppikar S.P. *Vitiligo And Psoriasis*;The Homeopathic Heritage. 1991;16(4):183-184.
14. Chimthanwala Kasim, *Leucoderma: a challenge*, National Journal of Homoeopathy. 1993; 2(2): 19-20,.
15. Talati Farida; *The Little Lady*, National Journal of Homoeopathy. 1993; 2(2): 30-31.
16. Gnanasambandam K, *A case of Vitiligo*, 1(11):13-14, Homoeo Times, November 2004.
17. Wadia S.R. *Leucoderma treated with Bowel Nosodes*; Homoeopathic Up- Dates. 1995;3(5):207-208.
18. Wadia S.R. *Leucoderma: a Social Stigma for Ladies*; National Journal of Homoeopathy. 1993; 2(2):10-17.
19. Wadia S.R. *Leucoderma (Vitiligo), Brief history and the Homoeopathic View point*;The Homeopathic Heritage. 2004; 29(10):38-43,.
20. Patwardhan Prabha. *The Wild Cat*; National Journal of Homoeopathy. 1993; 2(2):32-33.
21. Hahnemann S. *Organon of Medicine*; 5th & 6th Edition; New Delhi; B.Jain Publishers (P) Ltd. 1996.